

University of Pennsylvania
TEC2 Next Level
November 2016

Case report: retreatment, one year follow up

Dr. Claudia Michl, M.Sc.

DentoDoc

Carl-Jordanstraße 9

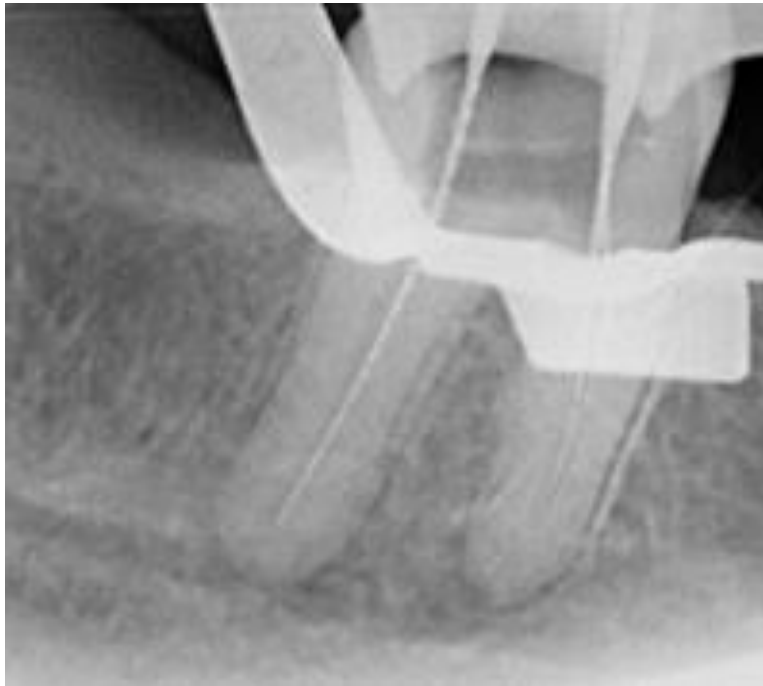
D-83059 Kolbermoor



DentoDoc

Claudia Michl und Team

Starting point



DentoDoc
Claudia Michl und Team

Starting point

- ▶ 55 year old patient with acute pain in the 4.th quadrant

Referred to us because of persistent pain during root canal treatment

Cavity tooth 47 only filled with a cotton pellet

- ▶ X-ray : root canal instruments iside, apical parodontitis mesial and distal



Examination

- ▶ 1. percussion tooth 47 :
 - ▶ 47 definitely positive
- ▶ 2. pulp test with dichlorofluoromethane (cold spray):
 - ▶ 47 negative
- ▶ 4. parodontal screening: PSI 2
- ▶ 5. palpation in area 47:
 - ▶ No pain apical

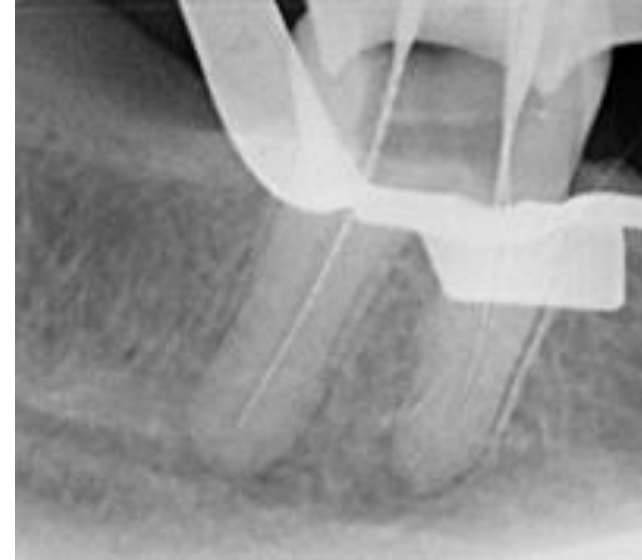


Diagnosis

Pulpa necrosis and symptomatic apical
parodontitis tooth 47

Treatment recommendation:

- ▶ Endodontic treatment at tooth 47 with dental operating
- ▶ microscope
- ▶ Removal of caries prior to opening of pulp
- ▶ Trepanation, preparation of a straightline access Cavity
- ▶ Treatment of root channels down to apical constriction
- ▶ Disinfektion
- ▶ Opturation und occlusal closure with Composite
- ▶ Prothetic suply of tooth 27 with gold or ceramic crown



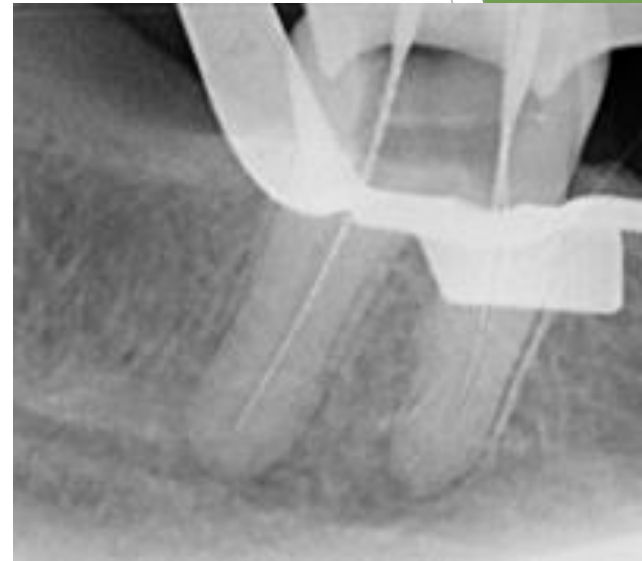
X-ray upon endometric legth measurement

X-ray mesial eccentric

Mb: 19mm (Iso10 R)

Ml: 19mm (iso10)

D: 19mm (Iso 20 H)



Treatment and Disinfection

BioRaCe

Preparation of path 010,015, under humid conditions

Reamer 010,015, manually

BR0 coronal opening of channel entry

Verification of path with file

Reamer 015,020

BR1, BR2, BR3 shaping coronal and middle channel third

BR4, BR5, BR6, BR7 shaping apical channel third, Distal BR7, Mesial BR6

irrigation protocol

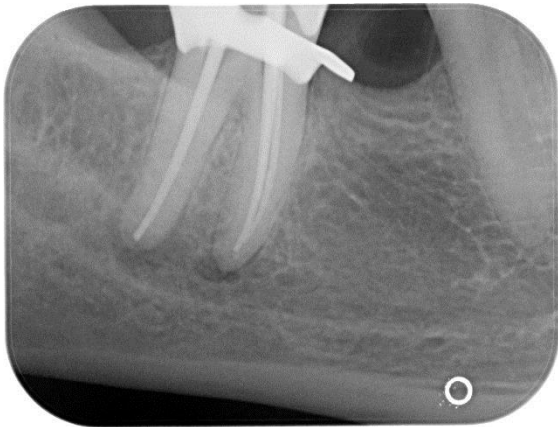
- **1. treatment:** changing lavage 3,5% NaOCl, 17% EDTA, processing at humid conditions, CHX 2%
- Ultrasonication of lavage solutions
- sustained injection of CaOH into the root channel
- **2. treatment:** analog 1. treatment without ultrasonication
- Drying and obturation of channels



Opturation

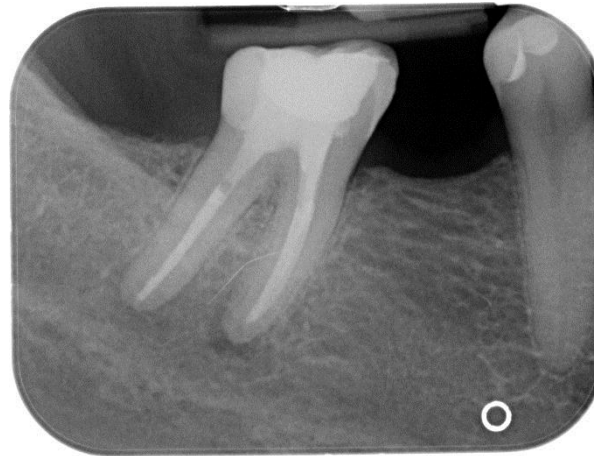
Single Cone Opturation Technique Guttapercha und TOTAL Fill

► Masterpoint



posttreatment radiograph

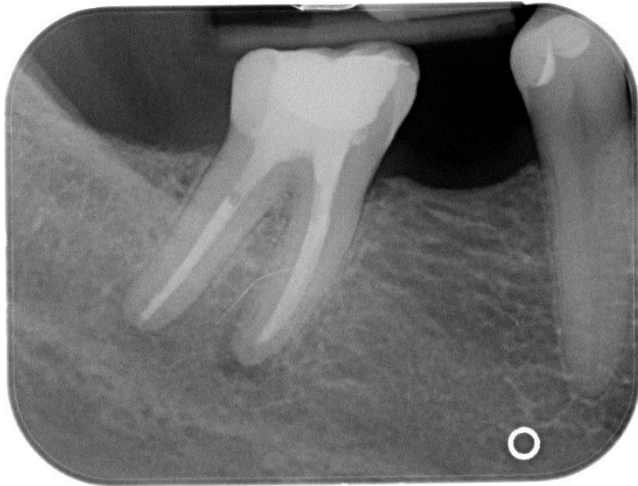
- Opturation and cover the floor of the pulp chamber with a line of bonded material after removal of excess gutta-percha to the canal orifice



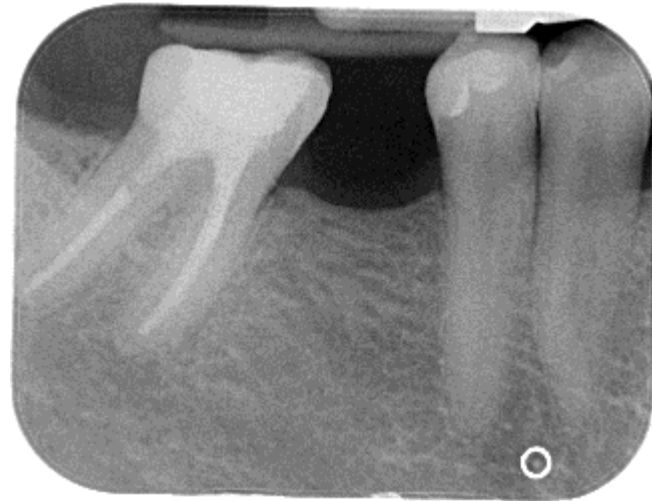Opturation

Single Cone Opturation Technique Guttapercha und TOTAL Fill

posttreatment radiography



one year later



DentoDoc
Claudia Michl und Team

Epicrisis

- ▶ Due to insufficient pain treatment, the 55 year old patient was assigned to us
- ▶ The previous dentist supposed additional channels, which he, however, did not find without a microscope
- ▶ As a consequence, he resigned a closure of the tooth so that it remained open
- ▶ During examination of tooth 47 a not sufficiently dimensioned access cavity was visible at first sight as well as a pulp floor, which was contaminated with food leftovers



Epicrisis

As the tooth was not closed and was definitely percussion positive it was inferred that the whole channel system down to the periapical tissue was infected

Therefore the therapy was started with a pulp necrosis, which means it was a priority to rework the area of the apical constriction and the apical channel third. Both of the mesial channels could be treated up to BR6, while the distal channel was treated up to BR 7. This equals an iso circumference of mesial 50 and distal 55. The therapy processed without complications.



Epicrisis

The prognosis for the tooth has to be seen. Although the x-ray scans one year after the root channel treatment indicated a heal up of the periapical tissue; also, the patient is without pain.


We filled the tooth with a composite filling and sealed the channels subcrestally with core material, however the patient did not agree to treat the tooth with a crown yet

Control X ray once a year is recommendable



Thanks for your attention

Questions?



DentoDoc
Claudia Michl und Team